

## Reduction of postoperative adhesions after laparoscopic gynecological surgery with Oxiplex/AP Gel\*: a pilot study

Phil Young, M.D.,<sup>a</sup> Alan Johns, M.D.,<sup>b</sup> Claire Templeman, M.D.,<sup>c</sup> Craig Witz, M.D.,<sup>d</sup> Bobby Webster, M.D.,<sup>e</sup> Roger Ferland, M.D.,<sup>f</sup> Michael P. Diamond, M.D.,<sup>g</sup> Kathleen Block, R.N.,<sup>h</sup> and Gere diZerega, M.D.<sup>c</sup>

<sup>a</sup>IGO Medical Group, San Diego, California; <sup>b</sup>Texas Institute of Clinical Research, Fort Worth, Texas; <sup>c</sup>Department of Obstetrics and Gynecology, Livingston Reproductive Biology Laboratories, Keck-University of Southern California School of Medicine, Los Angeles, California; <sup>d</sup>Department of Obstetrics and Gynecology, University of Texas Health Science Center at San Antonio, San Antonio, Texas; <sup>e</sup>Woman's Center for Fertility, Baton Rouge, Louisiana; <sup>f</sup>Women & Infants Hospital, Providence, Rhode Island; <sup>g</sup>Department of Obstetrics and Gynecology, Wayne State University School of Medicine, Hutzel Hospital, Detroit, Michigan; <sup>h</sup>FzioMed, Inc., San Luis Obispo, California

**Objective:** To determine whether Oxiplex/AP Gel (FzioMed, San Luis Obispo, CA) was safe and preliminarily effective in reducing postsurgical adhesions after adnexal surgery by laparoscopy.

**Design:** Prospective, multicenter, double-blind, randomized, U.S. Food and Drug Administration-monitored feasibility study.

**Setting:** University and private clinics.

**Patient(s):** Patients undergoing laparoscopic surgery with pelvic adhesions, tubal occlusion, endometriosis, and/or dermoids were randomized to receive Oxiplex/AP Gel or no further treatment after surgery.

**Intervention(s):** A blinded, parallel-group design was conducted at six centers. Patients (aged 18–46 years) underwent laparoscopic surgery, with second-look surgery 6–10 weeks later. Surgeries were videotaped. Oxiplex/AP Gel was used to cover adnexa and adjacent tissue.

**Main Outcome Measure(s):** Blinded reviews of videotapes were quantitated with the American Fertility Society adhesion score (AFS score).

**Result(s):** In 18 treatment patients, surgery was performed on 29 adnexa. Application of Oxiplex/AP Gel required approximately 90 seconds. In 10 control patients, surgery was performed on 18 adnexa. The mean baseline AFS score for each group was 8.0. At second look, treated adnexa had the same score (8.1), whereas in control adnexa the score increased (from 8.0 to 11.6). Thirty-four percent of treated adnexa increased in adhesion score, in contrast to 67% of control adnexa. There were no device-related adverse events.

**Conclusion(s):** In this pilot study, Oxiplex/AP Gel was safe, easy to use with laparoscopy, and produced a reduction in the increase of adnexal adhesion scores. (Fertil Steril® 2005;84:1450–6. ©2005 by American Society for Reproductive Medicine.)

**Key Words:** Adhesions, Oxiplex/AP Gel, surgery

Postoperative adhesion formation is the single greatest complication of gynecological surgery (1–3). Pelvic adhesions have been found in 56%–100% of patients undergoing second-look laparoscopy after primary gynecological surgery (4). Diamond

et al. (5) and DeCherney and Mezer (6) demonstrated that gynecological pelvic surgery typically causes adhesions to the adnexa. Rosen and Sutton (7) and Howard et al. (8) recently summarized the contribution of adnexal adhesions to infertility and pain. Although most conservative gynecological surgery is performed by laparoscopy, there are no adhesion prevention devices that can be easily delivered with laparoscopy.

Oxiplex/AP Gel (FzioMed, San Luis Obispo, CA) was specifically formulated for laparoscopic application, with tissue adherence and persistence sufficient to prevent adhesion formation. A similar preparation of Oxiplex (Oxiplex/SP Gel) was shown to reduce back pain and leg weakness from epidural adhesions after lumbar surgery (9, 10).

Received October 27, 2004; revised and accepted April 20, 2005.

Support for this study was provided in part by FzioMed, Inc., San Luis Obispo, California. M.D. received financial compensation for work involved in this publication. G.D. was a consultant to FzioMed, Inc. K.B. is an employee of FzioMed, Inc.

Reprint requests: Gere S. diZerega, M.D., University of Southern California Keck School of Medicine, Livingston Reproductive Biology Laboratory, Department of Obstetrics and Gynecology, 1321 North Mission Road, Los Angeles, CA 90033 (FAX: 323-222-7038; E-mail: dizerega@usc.edu).

\* Oxiplex/AP Gel, FzioMed, Inc., San Luis Obispo, California.

Although adhesion prevention devices were first approved by the U.S. Food and Drug Administration (FDA) in 1989, today no product is available that is designed for laparoscopic applications to the adnexa. Oxiplex/AP Gel has been demonstrated in a number of animal models to be a safe and effective barrier to the formation of adhesions after peritoneal cavity surgery (11). This article reports the results of a pilot clinical trial designed to study the safety and preliminary effectiveness of Oxiplex/AP Gel as an adhesion prevention device for women undergoing adnexal surgery by laparoscopy. This pilot investigation evaluated the safety of the device in patients undergoing conservative gynecological surgery, its ease of use when applied with laparoscopy, and the ability of the gel to reduce postsurgical adnexal adhesions.

## MATERIALS AND METHODS

Oxiplex/AP Gel is a viscoelastic gel composed of polyethylene oxide and carboxymethylcellulose stabilized by calcium chloride. The clinical protocol was approved by each study site's institutional review board and was monitored by the FDA as a feasibility study. All patients participating in this study signed an informed consent form approved by their site's respective institutional review board.

Twenty-eight women of child-bearing potential requiring surgical therapy on at least one adnexum for adnexal adhesions, endometrioma, endometriosis, dermoid cyst, or tubal occlusion requiring tubal plasty were randomized in a 2:1 ratio to either a treatment group receiving surgical therapy plus Oxiplex/AP Gel ( $n = 18$ ) or a control group receiving surgical therapy alone ( $n = 10$ ). After the standard surgical treatment was completed and before closing, the investigator contacted a central office for subject study group assignment. Selection of group assignment was random and not available to the investigator until all inclusion and exclusion criteria were met, including those determined during surgery.

In subjects randomized to the treatment group, Oxiplex/AP Gel was used to cover the adnexa, ovarian fossa, lateral uterus, and other anatomical sites that the surgeon felt were areas where adhesions might form ( $n = 18$ ). Subjects randomized to the control group received standard laparoscopic surgical therapy. In some patients, more than one adnexum was treated, as determined by the clinical indication for surgical therapy. Second-look laparoscopic surgeries were performed 6–10 weeks after the primary surgery.

All surgeries were recorded, and the videotapes were forwarded to a single masked reviewer to assess the performance of the gel and determine its ability to mitigate the formation of adhesions at the surgical sites. The adhesions at both primary surgery and second-look surgery were scored according to the system devised by the American Fertility Society (12). The videotapes also allowed a visual assessment of device biocompatibility.

American Fertility Society adnexal adhesion scores (AFS scores) were determined by assessing the extent (area of

adnexal organ covered by adhesions) and severity (severe: if the adhesion requires cutting to remove or tears peritoneal surfaces when removed bluntly or requires hemostasis; filmy if not severe) of the adhesions involving the fallopian tube and ovary. Summing the scores for the fallopian tube and the ovary provided a clinical category for the adhesion score: minimum (0–5), mild (6–10), moderate (11–20), and severe (21–32).

Safety evaluation was based on the patient's postoperative condition and recovery, as well as the type and severity of adverse events recorded throughout the study.

## Technique of Oxiplex/AP Gel Application

For patients who received Oxiplex/AP Gel, the following procedures were followed. At the end of surgery, subjects were placed in a reverse Trendelenburg position to facilitate collection of residual fluid from the cul-de-sac. Thereafter, residual fluid was aspirated until  $<10$  mL of fluid remained in the cul-de-sac. A single layer of gel was applied with a  $30.5 \text{ cm} \times 5 \text{ mm}$  canula applicator in sufficient volume to completely coat the surgical site with a viscous layer of gel. The gel treatment sites included the anterior and posterior surfaces of the ovary, fallopian tube including mesosalpinx, the surfaces between the fallopian tube and the ovarian surface, adjacent pelvic sidewall including the ovarian fossa, and the lateral aspect of the uterus that could come in contact with the adnexa. The amount of gel required to coat the adnexa and adjacent tissues on a single side did not exceed 30 mL. Thereafter, the surgical instruments were removed, and the pneumoperitoneum evacuated.

## Statistical Analysis

The treatment and control groups were compared by Student's *t*-test for continuous variables and Fisher's exact test for categorical variables. The number and proportion of sites with adhesions were compared by Student's *t*-test. Adhesion scores were compared by the Wilcoxon rank-sum test, and shift tables were analyzed by the Cochran-Mantel-Haenszel test, with the *ridit* scores based on the order of adhesion score categories.

## RESULTS

There was no difference in the demographic distribution in terms of race, weight, duration of surgery, or estimated blood loss between patients in the Oxiplex/AP Gel-treated and control groups (Table 1). The most commonly performed surgical procedure was adhesiolysis (in 88% of the treated and all of the control patients). Two control patients underwent removal of an endometrioma, and one of the treated patients had bilateral neosalpingostomies. One treated patient underwent removal of a dermoid cyst. Endometriosis was the most commonly found pathology (treatment: 72%; control: 90%). Most of the patients had undergone previous surgery (treatment: 66%; control: 30%).

**TABLE 1****Demographic data and medical and surgical history.**

Variable	Study group	
	Oxiplex/AP Gel	Control
Patients	18	10
Age (y)	31.1 ± 0.9	32.6 ± 1.2
Ethnic group		
Caucasian	12	6
Asian or Pacific Islander	1	2
Black	2	0
Hispanic	3	2
Weight (lb)	137.1 ± 3.5	136.1 ± 7.0
Estimated blood loss (mL)	57.2 ± 9.2	55.0 ± 18.4
Duration of surgery (h)	1.9 ± 0.2	2.0 ± 0.6
Surgical procedures performed		
Laparoscopy, with lysis of adhesions	16	10
Laparoscopy with fulguration or excision of lesions of the ovary or pelvic viscera	12	8
Removal of endometriosis	9	5
Chromotubation of oviduct	4	6
Bilateral neosalpingostomy	1	0
Removal of dermoid cyst	1	0
Removal of endometrioma	0	2

Note: Data are presented as n or mean ± SEM.

Young. Oxiplex/AP Gel reduction of adhesions. *Fertil Steril* 2005.

All patients tolerated the surgical procedures well, were discharged home within 24 hours of their surgical procedures, and had unremarkable postoperative courses, except for one treated patient who developed mild food poisoning. There were no reports of prolonged constipation, fevers, or postoperative pain requiring evaluation or hospitalization. There were no clinically significant alterations in laboratory values. Of the adverse events reported, none were attributed to the use of the device. No deaths occurred during this study, and there were no study discontinuations due to an adverse event. There were no unexpected adverse events or abnormalities in laboratory values or vital signs. All patients returned for second-look laparoscopy except one of the treated patients (one layer of gel, 18 mL), who became pregnant within 6 weeks of her initial surgery.

In this pilot clinical study, 28 patients underwent laparoscopic surgical therapy of their adnexa to remove existing adhesions or endometriosis. During the initial surgical procedure, 18 adnexa in the control group and 29 adnexa in the treated group underwent surgical therapy. All of these adnexa were entered into the analyses. Oxiplex/AP Gel was applied over the surface of the fallopian tubes, ovaries, ovarian fossae, and lateral portion of the uterus.

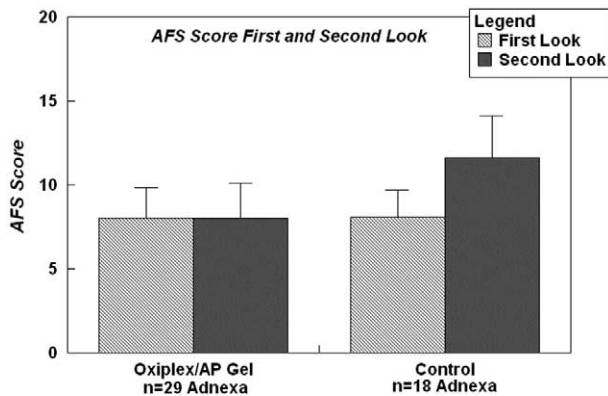
The AFS adhesion scores (12) were determined at both first and second look for 29 adnexa in the treated group

and 18 adnexa in the control group. The mean AFS score was the same at the time of initial surgery (8.0) for the treatment and control groups. The mean AFS score for patients in the treatment group was essentially unchanged at the time of second-look laparoscopy (8.1). In contrast, the AFS score for the control patients increased to 11.6 (Fig. 1). At second look, twice the number (66.7%) of control adnexa had an increased AFS score, compared with (34.5%) of the treated adnexa (Fig. 2). This 32% reduction in adhesion formation, as shown by the change in AFS score, is a clinically significant improvement in patient outcome (13).

When adnexa were stratified by AFS score at primary surgery, the benefit of Oxiplex/AP Gel treatment to the adnexa with greater disease was evident through a reduction in the increase of AFS scores. For adnexa with AFS scores <6 at primary surgery, the change in mean score between first and second surgeries was 1.9 for the treated vs. 2.6 for the control group. For adnexa with AFS scores ≥6 at primary surgery, the change in mean scores was -1.0 in the treated vs. 4.9 in the control group. Sixty-two percent of the adnexa in the control group that had an initial AFS score of ≥6 increased their AFS score at second look. In contrast, only 28% of the Oxiplex/AP Gel-treated adnexa had an increase in their AFS score (Fig. 3).

**FIGURE 1**

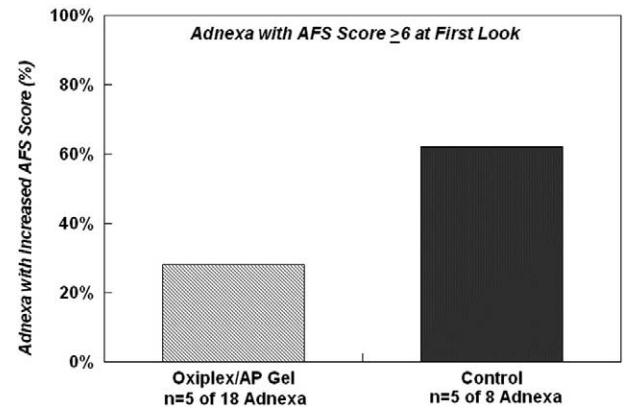
American Fertility Society adnexal adhesion score (AFS Score) at first surgery and second-look surgery in the treatment and control groups.



Young. Oxiplex/AP Gel reduction of adhesions. *Fertil Steril* 2005.

**FIGURE 3**

Adnexa with AFS score  $\geq 6$  at first surgery in the treatment and control groups.



Young. Oxiplex/AP Gel reduction of adhesions. *Fertil Steril* 2005.

As the investigators gained experience during their initial applications of Oxiplex/AP Gel, it was determined that a single layer of gel was sufficient to cover the adnexal surfaces; multiple layers were not necessary. The mean volume to cover an adnexum and adjacent surfaces was approximately 15 mL. The time required to cover the adnexal surfaces, lateral uterus, and adjacent sidewall including the ovarian fossa was approximately 90 seconds. The gel adhered well to all surfaces, including those that were gravitationally dependent.

In this pilot study, Oxiplex/AP Gel was demonstrated to be safe and provided site-specific adhesion reduction when applied to adnexal surfaces. Although the sample size of this

pilot study was relatively small, the results provide a demonstration of device safety and efficacy.

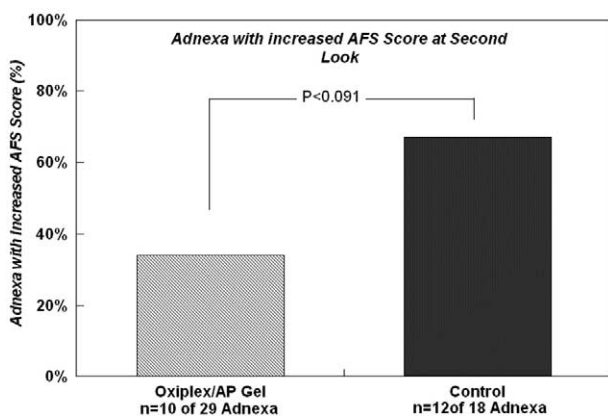
## DISCUSSION

The primary objective of this pilot study was to determine the safety of covering surgically treated areas of the adnexa and adjacent peritoneal surfaces with Oxiplex/AP Gel during laparoscopic surgery after removal of adhesions, endometriosis, or endometriomas. The primary safety parameters were adverse events and clinical laboratory test values. As a secondary objective, the techniques of applying Oxiplex/AP Gel were assessed to determine the optimal steps to maximize patient benefit and ease of use for the surgeon. In addition, general effectiveness of the gel was evaluated to help design further studies with sufficient statistical power to demonstrate the efficacy of Oxiplex/AP Gel in preventing pelvic adhesions (14).

In this pilot clinical study, 28 patients underwent laparoscopic surgical therapy of their adnexa to remove existing adhesions, endometriomas, or endometriosis. After the primary surgical procedure(s), the patients randomized to the treatment group (n = 18) had Oxiplex/AP Gel applied to their adnexa that had undergone surgical therapy. Oxiplex/AP Gel was applied over the surface of the fallopian tubes, ovaries, ovarian fossae, and lateral portions of the uterus. With the experience gained from the first applications of the gel, it was determined that a single layer of gel was sufficient to cover the adnexal surfaces; multiple layers were not necessary. For this site-specific barrier, coverage of an area at risk for adhesion formation was the critical factor, not absolute volume, as would be important with an intraperitoneal instillate. The mean volume to cover an adnexum was approximately 15 mL. The time required to cover the adnexal surfaces was approximately 90 seconds. The gel ad-

**FIGURE 2**

Adnexa with increased AFS score at second-look surgery in the treatment and control groups.



Young. Oxiplex/AP Gel reduction of adhesions. *Fertil Steril* 2005.

hered well to all surfaces, including those that were gravitationally dependent.

A single layer of gel was sufficient to protect the tissue during postsurgical repair. The gel was cleared from the peritoneal cavity before the time of second-look laparoscopy, usually within 6 weeks. In four cases in which large amounts of gel, applied in multiple layers, were applied to the surgically treated sites (60 mL, 30 mL, 30 mL, and 23 mL), small collections (approximately  $5 \times 5$  mm) of gelatinous material (presumably residual gel) were noted in areas of gel application or in areas deep in the cul-de-sac where intraperitoneal clearance might have been affected (15, 16), particularly in cases of stage IV endometriosis (17), in which the cul-de-sac is obliterated. In two instances, biopsies of these sites were consistent with residual gel. There did not seem to be any clinical significance to the residual gel because the residuum did not interconnect tissue surfaces, was not associated with adhesions, and did not obstruct organ mobility. Although it is reassuring to see gel persisting at the site of application, avoidance of applying excess gel is recommended. Reproductive toxicology studies performed with Oxiplex as part of an FDA filing were negative.

Oxiplex/AP Gel is composed of carboxymethylcellulose (CMC) and polyethylene oxide (PEO) stabilized by calcium. Polymers containing either CMC or PEO were reported to reduce formation of postoperative adhesions in a variety of animal models. Initially, Elkins et al. (18, 19) showed that 0.9% and 1.0% CMC were effective in reducing adhesions to the rat cecum treated with CMC. Subsequently, Frederick et al. (20) demonstrated a reduction of adhesions in a rabbit model, which was shown to be superior to 32% dextran 70. Diamond et al. (21) evaluated CMC in different volumes and concentrations with and without 32% dextran in a rabbit uterine horn model. Carboxymethylcellulose alone was effective in reducing adhesions, whereas dextran provided no additional benefit. In these studies, an inverse correlation was noted between either the concentration of CMC (1%, 2%, and 3%) or the volume of 2% CMC (20 mL, 30 mL, 40 mL, and 50 mL) and the extent of adhesion formation. The best results were reported with the highest viscosity (94,000 cps) CMC at the largest volume (50 mL).

Diamond et al. (22) confirmed and extended these observations in an adhesion reformation model. Reduction of adhesions by CMC was also shown after bowel surgery. Wurster et al. (23) reported that a 12 mL solution of 1% CMC reduced adhesions to the rat cecum after generalized abrasion of the small bowel serosa and, in a separate group of animals, that there was no impairment in anastomotic healing. It has been hypothesized by Leach et al. (24) that coating the tissue surfaces decreases the injured tissue apposition required for adhesion formation.

Polyethylene oxide is a nonionic, water-soluble polymer widely used for stabilizing colloids and in formulating pharmaceuticals. Because of the biocompatibility of PEO and its solubility in aqueous solution, PEO is used to coat a variety

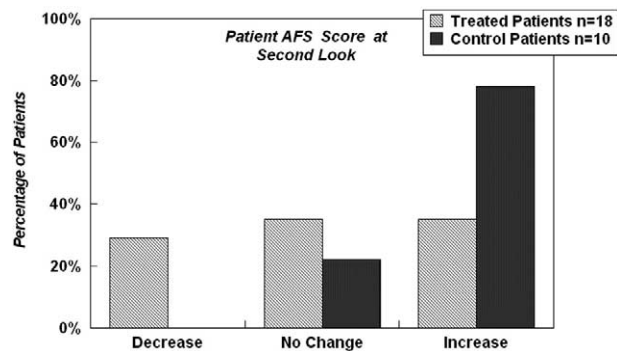
of materials to limit their interaction with proteins (25). It is widely used as a dispersant because it is inert and noninflammatory. In particular, fibrin and fibrin gel matrix, precursors to the fibrin bridges that interconnect apposing surfaces leading to adhesions (26), do not interact well with PEO (27). Steric repulsion forces between PEO and protein in aqueous solutions prevent binding of complex proteins like fibrin to PEO.

Various volumes of PEO were shown to reduce adhesions in animal models (28, 29). However, the volumes required to achieve meaningful results preclude clinical use (30). Materials composed of both CMC and PEO, in the form of films and gels, have been demonstrated to reduce adhesions in a variety of animal models (11, 30). Carboxymethylcellulose is tissue adhesive and provides a barrier function. Polyethylene oxide inhibits the interaction of proteins and functions with the CMC to limit tissue interaction. When CMC and PEO are stabilized into a composite gel, the properties of protein repulsion and tissue adherence are additive in preventing postsurgical adhesions (31).

Clinical measurement of adhesions was performed with the American Fertility Society adnexal adhesion classification (AFS score) (12). Adhesion scoring systems were developed to help establish correlations between adhesions and disease outcomes to guide management. These correlations are most clearly established when adhesions are graded numerically rather than simply qualitatively. Adhesion scoring is not only used for prognosis, but it can also be a determinant of therapy (32). The most widely used system is the AFS score (12). The AFS score is a method for classifying pathology that takes into account the extent and anatomical location of adhesions. This system is limited to the surface of the ovaries and fallopian tubes, and each adnexum is scored separately. Scores are assigned on the basis of the type (filmy or dense) and extent (fraction of the organ covered) of the adhesion. After summing the score for the fallopian tube and the ovary, the degree of adhesion is classified as minimal (0–5), mild (6–10), moderate (11–20), or severe (21–32).

Clinical correlations using the AFS score have been previously summarized (14). The AFS score was designed to predict the patient's chance of becoming pregnant, according to the adnexa with the lower score (14). On a per-patient basis, by selecting the adnexa with the lower score, 29% of the treated patients had an improvement in their score, 35% had no change in score, and 35% had a worsening of score. This is in contrast to the control patients, of whom 78% had a worse adhesion score at second-look surgery, 22% had no change, and no patient had an improvement in score (Fig. 4).

In general, patients with minimal adhesion scores do well; in contrast, those with severe adhesion scores do poorly. Recently, the FDA recommended that the AFS score be used as a clinical outcome measure in clinical studies of devices intended to reduce postsurgical adhesion formation (33).

**FIGURE 4****Changes in patient AFS scores at second-look surgery.**

Young. Oxiplex/AP Gel reduction of adhesions. *Fertil Steril* 2005.

In conclusion, Oxiplex/AP Gel was found to be safe and easy to use during laparoscopic surgery. There was a marked reduction in the number of adnexa that had an increase in adhesions when treated with Oxiplex/AP Gel, compared with surgery-only controls. A similar benefit in adhesion reduction was recently reported from a multicenter study performed in Europe (34). Confirmation of these results is required in a follow-up pivotal study.

**Acknowledgments:** The authors thank Rebecca Weegar for her technical support throughout the study and Trish Lyons for her editorial assistance in the preparation of this article.

## REFERENCES

- Tulandi T. Introduction-prevention of adhesion formation: the journey continues. *Hum Reprod Update* 2001;7:545-6.
- Al-Musawi D, Thompson JN. Adhesion prevention: state of the art. *Gynecol Endosc* 2001;10:123-30.
- Lower AM, Hawthorn RJS, Ellis H, O'Brien F, Buchan S, Crowe AM. The impact of adhesions on hospital readmissions over ten years after 8849 open gynaecological operations: an assessment from the Surgical and Clinical Adhesions Research Study. *Br J Obstet Gynecol* 2000; 107:855-62.
- Schwartz LB, Diamond MP. Formation, reduction and treatment of adhesive disease. *Semin Reprod Endocrinol* 1991;9:89-99.
- Diamond MP, Daniell JF, Feste J. Adhesion formation and de novo adhesion formation after reproductive pelvic surgery. *Fertil Steril* 1987; 47:864-6.
- DeCherney AH, Mezer HC. The nature of posttuboplasty pelvic adhesions as determined by early and late laparoscopy. *Fertil Steril* 1984; 41:643-6.
- Rosen DMB, Sutton CJG. Outcome measures and adhesion formation: pain and postsurgical adhesion. In: diZerega GS, ed. *Peritoneal surgery*. New York: Springer-Verlag, 2000:321-7.
- Howard FM, El-Minawi AM, Sanchez RA. Conscious pain mapping by laparoscopy in women with chronic pelvic pain. *Obstet Gynecol* 2000; 96:934-9.
- Kim KD, Wang JC, Robertson DP, Brodke DS, Olson EM, Duberg AC, et al. Reduction of radiculopathy and pain with Oxiplex/SP Gel after laminectomy, laminotomy, and discectomy. *Spine* 2003;28:1080-7.
- Kim KD, Wang JC, Robertson DP, Brodke DS, BenDebba M, Block KM, et al. Reduction in leg pain and lower-extremity weakness with Oxiplex/SP Gel for 1 year after laminectomy, laminotomy, and discectomy. *Neurosurgical Focus* 2004;17:ECP1.
- Rodgers KE, Schwartz HE, Roda N, Thornton M, Kobak W, diZerega GS. Effect of Oxiplex films (PEO/CMC) on adhesion formation and reformation in rabbit models and on peritoneal infection in a rat model. *Fertil Steril* 2000;73:831-8.
- The American Fertility Society. The American Fertility Society classification of adnexal adhesions, distal tubal occlusion, tubal occlusion secondary to tubal ligation, tubal pregnancies, Müllerian anomalies and intrauterine adhesions. *Fertil Steril* 1988;49:944-55.
- Lydick E, Epstein RS. Interpretation of quality of life changes. *Qual Life Res* 1993;2:221-6.
- diZerega GS, Roth R, Johns DB. Quantitation of peritoneal adhesions and correlation with clinical outcomes. *Infert Reprod Med Clin N Am* 2003;14:431-56.
- Ahrenholz DH, Simmons RL. Peritonitis and other intra-abdominal infections. In: Howard RJ, Simmons RL, eds. *Surgical infectious disease*. 2nd ed. East Norwalk, CT: Appleton & Lange, 1988:624.
- diZerega GS, Rodgers KE. *The peritoneum*. New York: Springer-Verlag, 1992:33.
- Nisolle M, Donnez J. Peritoneal endometriosis, ovarian endometriosis, and adenomyotic nodules of the rectovaginal septum are three different entities. *Fertil Steril* 1997;68:585-96.
- Elkins TE, Bury RJ, Ritter JL, Ling FW, Ahokas RA, Homsey CA, et al. Adhesion prevention by solutions of sodium carboxymethylcellulose in the rat. I. *Fertil Steril* 1984;41:926-8.
- Elkins TE, Ling FW, Ahokas RA, Abdella TN, Homsey CA, Malinak LR. Adhesion prevention by solutions of sodium carboxymethylcellulose in the rat. II. *Fertil Steril* 1984;41:929-32.
- Frederick CM, Kotry I, Holtz G, Askalani AH, Serour GI. Adhesion prevention in the rabbit with sodium carboxymethylcellulose solutions. *Am J Obstet Gynecol* 1986;155:667-70.
- Diamond MP, DeCherney AH, Linsky CB, Cunningham T, Constantine B. Assessment of carboxymethylcellulose and 32% dextran 70 for prevention of adhesions in a rabbit uterine horn model. *Int J Fertil* 1988;33:278-82.
- Diamond MP, DeCherney AH, Linsky CB, Cunningham T, Constantine B. Adhesion re-formation in the rabbit uterine horn model: I. Reduction with carboxymethylcellulose. *Int J Fertil* 1988;33:372-5.
- Wurster SH, Bonet V, Mayberry A, Hoddinott M, Williams T, Chaudry IH. Intraperitoneal sodium carboxymethylcellulose administration prevents reformation of peritoneal adhesions following surgical lysis. *J Surg Res* 1995;59:97-102.
- Leach RE, Burns JW, Dwae EJ, SmithBarbour MD, Diamond MP. Reduction of postsurgical adhesion formation in the rabbit uterine horn model with use of hyaluronate/carboxymethylcellulose gel. *Fertil Steril* 1998;69:415-8.
- Arakawa T, Timasheff SN. Mechanism of poly (ethylene glycol) interaction with proteins. *Biochemistry* 1985;24:6756-62.
- diZerega GS. Peritoneum, peritoneal healing, and adhesion formation. In: diZerega GS, ed. *Peritoneal surgery*. New York: Springer Verlag, 2000:3-37.
- Golander CG, Herron JN, Claesson KL, Stenius P, Andrade JD. In: Harris JM, ed. *Properties of immobilized PEG films and the interaction with proteins: experiments and modeling*. Poly (ethylene glycol) chemistry: Biotechnical and biomedical applications. New York: Plenum, 1992:221-45.
- O'Sullivan D, O'Riordain M, O'Connell RP, Dineen M, Brady MP. Peritoneal adhesion formation after lysis: inhibition by polyethylene glycol 4000. *Br J Surg* 1991;78:427-9.
- Nagelschmidt M, Saad S. Influence of polyethylene glycol 4000 and dextran 70 on adhesion formation in rats. *J Surg Res* 1997;67:113-8.
- Robertson JT, Blackmore J, Oppelt W, Smith JS, diZerega GS, Rodgers KE. Reduction of peridural fibrosis by Oxiplex after laminectomy in a rabbit model. Paper presented at: Annual Meeting of the

American Association of Neurosurgeons; April 21, 2001; Toronto, Canada.

31. Liu LS, Berg RA. Adhesion barriers of carboxymethylcellulose and polyethylene oxide composite gels. *J Biomed Mater Res* 2002;63:326–32.
32. Mage G, Pouly JL, de Joliniere JB, Chabrand S, Riouallon A, Bruhat MA. A preoperative classification to predict the intrauterine and ectopic pregnancy rates after distal tubal microsurgery. *Fertil Steril* 1986;46:807–10.
33. U.S. Food and Drug Administration, Department of Health and Human Services. Guidance for resorbable adhesion barrier devices for use in abdominal and/or pelvic surgery; guidance for industry. Rockville, MD: U.S. Department of Health and Human Services, 2002.
34. Lunderoff P, Donnez J, Korell M, Audebert AJM, Block K, diZerega GS. Clinical evaluation of a viscoelastic gel for reduction of adhesions following gynaecological surgery by laparoscopy in Europe. *Hum Reprod* 2005;20:514–20.